

Olgu sunumu / Case report

Ventriküloperitoneal şantın nadir bir komplikasyonu; Abdominal serebrospinal psödokist. Olgu sunumu.

A RARE COMPLICATION OF VENTRICULOPERITONEAL SHUNT; ABDOMINAL CEREBROSPINAL PSEUDOCYST. A CASE REPORT.

Mehmet Seçer¹, Ali Dalgıç¹, Mutlu Doğanay², Fatih Altıntoprak³

Ankara Numune EA Hastanesi, 2. Beyin Cerrahi Kliniği¹, Genel Cerrahi Kliniği, Ankara
Sakarya Üniversitesi Tıp Fakültesi, Genel Cerrahi ABD² Sakarya / Türkiye

Cer San D (J Surg Arts), 2011;4(1):14-16.

Bu makale; 2010, Ankara, 17. Ulusal Cerrahi Kongresi'nde sunulmuştur.

ABSTRACT

Abdominal cerebrospinal pseudocyst (CSF-P) is a rare complication of ventriculoperitoneal shunt (VPS). A 40-year-old man applied to emergency service with the complaints of abdominal pain, headache, nausea and vomiting. He had a VPS application history in 16 years ago. A cystic mass lesion which filled at the right subdiaphragmatic and subhepatic area and peritoneal catheter ended in it was detected on the abdominal computed tomography (CT). Partial cyst excision and shunt revision operation was performed. This case presented for rare incidence and emphasize that the possibility of CSF-P in the patients whom admitted with abdominal complaints, headache and VPS history.

Key words: Ventriculoperitoneal shunt; hydrocephalus; abdomen; pseudocyst

ÖZET

Abdominal serebrospinal psödokist gelişimi ventriküloperitoneal şant (VPS) uygulamalarının nadir görülen bir komplikasyonudur. 40 yaşında erkek hasta acil servise karın ağrısı, baş ağrısı, bulantı ve kusma şikayetleri ile başvurdu. Hikayesinde hastaya 16 yıl önce VPS uygulaması yapıldığı saptandı. Abdominal bilgisayarlı tomografi incelemesinde sağ subdiyafragmatik ve subhepatik alanı dolduran ve içinde peritoneal kataterin ucunun sonlandığı görülen kistik kitle saptandı. Parsiyel kist eksizyonu ve şant revizyonu ameliyatı uygulandı. Olgu nadir görülmesi ve VPS uygulaması olan hastalarda gelişen karın ağrısı ve baş ağrısı şikayetleri varlığında bu nadir komplikasyonun olabileceğinin hatırlatılması amacıyla sunulmuştur.

Anahtar kelimeler: Ventriküloperitoneal şant; hidrocefali; karın; psödokist

INTRODUCTION

Abdominal cerebrospinal pseudocyst after ventriculoperitoneal shunt (VPS) was first described by Harsh in 1954 (1). It is a rarely seen complication and the incidence rate is between 1% and 4.5% (2,3). Although is accepted that it occurs secondary to intraabdominal inflammation which develops in the presence of preliminary factors, such as infection, obstruction and migration of peritoneal catheter, its exact etiology has not been understood. Clinically, it may presented with nonspecific gastrointestinal complaints, such as abdominal pain, distension, and vom-

ting apart from neurological symptoms (4). Because of a rare clinical entity, cases are limited and therefore, there has been no consensus on a treatment algorithm.

Case report

The 40-year-old man was admitted with complaints of abdominal pain, headache, vomiting and nausea. The VPS application that due to an obstructive hydrocephaly related to an intracranial mass in 16 years ago was occur in the patient history. The neurological examination was normal; however, a mass that regularly contoured, soft and moved with respiration

was detected at the right upper quadrant in the abdomen. All hematological and biochemical parameters were normal. The cranial CT showed a ventricular catheter that it was inserted in right lateral ventricle through right parietal region and a nodular hyperdense mass in the third ventriculus (Figure 1). A cystic mass which the size of 16x12 cm, regularly contoured and the peritoneal catheter ended in it was detected in the abdominal CT (Figure 2). During the operation, the wall of the cystic mass was partially excised, peritoneal catheter of the shunt was revised and it was replaced to right paracolic area. After the operation, the patient did not have any headache. In the biochemical and microbiological examinations of the liquid taken from the cystic mass were normal.

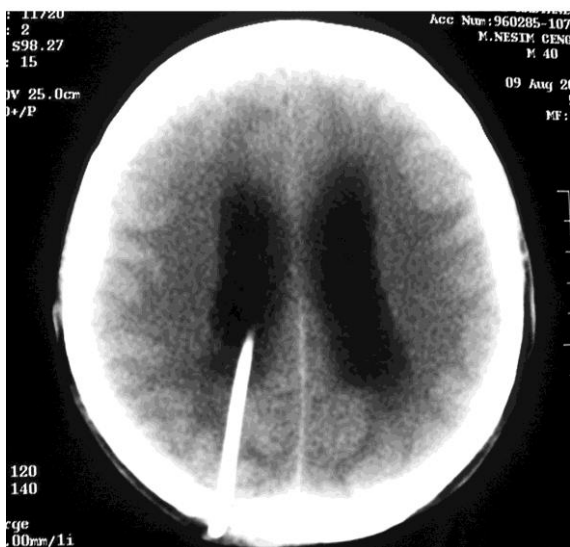

Figure 1: Cranial CT, showed that a ventricular catheter was inserted in right lateral ventricle through right parietal region

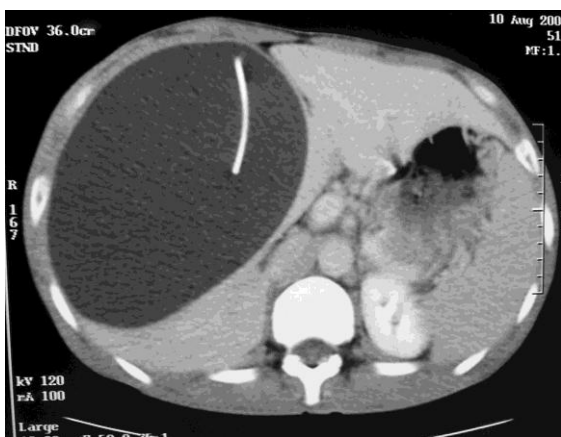


Figure 2: Abdominal CT, a cystic mass that regularly contoured, homogeneous internal structure, 16x12 cm in diameter

DISCUSSION

The traditional treatment of hydrocephaly is diverting of CSF flow from ventricular system into a

different cavity such as intrapleural or intraperitoneal area by using a shunt. For this purpose, the most commonly used method is VPS. The rate of ventriculoperitoneal shunt complications has been reported 26%, includes shunt dysfunction, infection, intestinal obstruction and visceral organ perforation (5). The other rare complications are subphrenic abscess, cerebrospinal-enteric fistula due to small intestine perforation, the migration of the peritoneal catheter to intratoracic or subdiaphragmatic area and the formation of abdominal pseudocyst (2,6).

Abdominal cerebrospinal pseudocyst is a rare complication in the VPS cases and the incidence of 1-4.5% (2,3). The etiology of CSF-P is controversial but the inflammation theory is the most accepted hypothesis in today that occurring in the presence of predisposing factors. The factors causing sterile inflammation are primer peritonitis and intestinal adhesion due to previous operations, multiple shunt revisions, and allergic reactions (7). Gaskil et al (8) reported that inflammation is the most frequent predisposing factor; on the other hand, Rainov et al (3) suggested that the microbiological infections is the most frequent predisposing factor. In our case, the widespread adhesions were detected in the abdominal exploration as the evidence of inflammation, however, no microorganisms grew in the liquid sample taken from the mass. The most frequent intraabdominal respond to inflammation is surrounded of shunt by peritoneum like a pouch. This cystic pouch may increasingly grow owing to CSF drainage.

The most common findings of abdominal CSF-P are abdominal pain (63%), distention (37%) and a palpable mass in the abdomen (29%) (4). In despite of in the pediatric patients with pseudocyst generally admit with the headache and nausea, because of increased intracranial pressure, adults have more local abdominal complaints. Although abdominal ultrasonography (USG) helps diagnose quickly and easily, the diagnosis must be made certain by using abdominal CT (9). In our case, when we saw that the intraabdominal peritoneal catheter is in a normal place, but abdominal CT revealed that the catheter is in the mass. Therefore we diagnosed CSF-P and decided to perform exploration.

Since the number of cases is limited, there has been no consensus over a method to treat pseudocyst. Treatment changes according to the characteristics of patients, experience of the surgeon, and the findings during the operation. Many authors recommend that temporary extraventricular drainage and appropriate antibiotic treatment in the presence of infection. Gaskil et al reported that mass resorbed without performing excision when CSF flow place is changed (8). Recently, minimal invasive procedures were described such as, cyst wall excision by laparoscopy, pseudocyst aspiration or excision with CT or USG, removal or revision of shunt, and intra atrial shunt. Rainov et al (3) suggested that identifyca-

tion of the peritoneal catheter and excision of the pseudocyst if possible by a small laparotomy.

In conclusion, although rarely, it is possible which intraabdominal CSF pseudocyst occur after VP shunt. This rare complication of VP shunt has to be considered if the patients who have VP shunt application in their history have seemingly nonspecific gastrointestinal complaints in addition to clinical symptoms of increase in the intracranial pressure such as unexplainable headache, nausea, and vomiting.

REFERENCES

1. Harsh GR: Peritoneal shunt for hydrocephalus utilizing the fimbria of the fallopian tube for entrance to the peritoneal fluid. *J Neurosurg* 1954; 11(3):284-94.
2. Agha FP, Amendola MA, Shirazi KK, Amendola BE, Chandler WF. Unusual abdominal complications of ventriculo-peritoneal shunts. *Radio-logy* 1983;146(2):323-6.
3. Rainov N, Schobess A, Heidecke V, Burkert V. Abdominal CSF pseudocyst in patients with ventriculo-peritoneal shunts. Report of fourteen cases and review of literature. *Acta Neurochir* 1994;27(1-2):73-8.
4. Pathi R, Sage M, Slavotinek J, Hanier A. Abdominal cerebrospinal fluid pseudocyst. *Australas Radiol* 2004;48(1):61-3.
5. Murtagh FR, Quencer RM, Poole CA. Extracranial complications of cerebrospinal fluid shunt function in childhood hydrocephalus. *Am J Roentgenol* 1980;135(4):763-6.
6. Mata J, Alegret X, Llauger J. Splenic pseudocyst as a complication of ventriculoperitoneal shunt: CT features. *J Comput Assist Tomogr* 1986; 10(2):341-2.
7. Hsieh CT, Pai CC, Tsai TH, Chiang YH, Su YH. Hepatic cerebrospinal fluid pseudocyst: A case report and review of the literature. *Neurol India* 2006;54(1):86-8.
8. Gaskill SJ, Marlin AE. Pseudocysts of the abdomen associated with ventriculoperitoneal shunts: A report of twelve cases and a review of the literature. *Pediatr Neurosci* 1989;15(1):23-7.
9. Sharma AK, Pandey AK, Diyora B. Abdominal CSF pseudocyst in a patient with ventriculoperitoneal shunt. *Indian J Surg* 2004;66(6): 360-3.