

Original study

Tracheal reconstruction using pericardium in emergency as a life saving procedure in cases of severe tracheal stenosis.

ACİL TRAKEAL STENOZ OLGULARINDA HAYAT KURTARICI BİR İŞLEM OLARAK PERİKARD İLE TRAKEA REKONSTRÜKSİYONU.

Dheeraj Sharma, Anula Sisodia, Sanjeev Devgarha, Rajendra Mohan Mathur

Department of CardioThoracic and Vascular Surgery, S.M.S Medical College, Jaipur, Rajasthan, India.

Corresponding address: Dr. Dheeraj Sharma, dr.dheeraj.123@gmail.com

J Surg Arts (Cer San D), 2017(2):14-18.

ABSTRACT

Post intubation tracheal stenosis followed by tracheostomy resulting in destruction of long segment of trachea remains a serious clinical problem. In this study we review our experience with technique of tracheal reconstruction using pericardial flap/patch as an emergency procedure to save life of patient.

Since Dec 2011 to Dec 2012, a total of 5 patients with tracheal stenosis as a result of intubation and tracheostomy were included in this study and examined for outcomes of stenosis management.

Our treatment strategy for treatment of long segment of tracheal stenosis with pericardial patch/flap was associated with good outcomes. The overall success rate was 80% with no early and late complications.

In conclusion, long term endotracheal intubation and tracheostomy results in destruction of long tracheal segment causing end to end and other repairs impossible. Therefore our technique for long segment tracheal stenosis using pericardium remains a good alternative in an emergency as a life saving procedure.

Key words: Tracheal reconstruction; tracheal stenosis; tracheostomy; pericardial flap.

ÖZET

İntubasyon sonrası ortaya çıkan stenoz ve takiben uzun segmenti içeren trakeostomiler ciddi klinik problemlere yol açarlar. Bu çalışmada, acil ve hayat kurtarıcı bir işlem olarak perikard ile yapılan trakeal rekonstrüksiyon olgularımızı gözden geçirdik.

Aralık 2012-2013 yılları arasında entübasyona bağlı olarak gelişen trakeal stenoz nedeniyle 5 hastamızda uyguladığımız tedavi sonuçları değerlendirildi.

Uzun segmentte gelişen trakeal stenoz olgularında yaklaşımımız perikardial flep ile rekonstrüksiyon yaparak iyi sonuçlar aldık. Erken vfe geç komplikasyon olmaksızın olguların %80'inde başarılı sonuç aldık.

Sonuç olarak, uzun segmenti tutan trakeal entübasyon ve trakeostomiler sonrasında oluşan hasarın primer tamiri imkansız hale gelmektedir. Buyüzden bizim kullandığımız teknikte, trakeanın perikard ile sarılması hayat kurtaran bir işlem gibi gözükmektedir.

Anahtar kelimeler: Trakea; stenoz; trakeostomi; rekonstrüksiyon; perikard.

INTRODUCTION

Post intubation tracheal stenosis represents the most common iatrogenic injury of trachea. It occurs after intubation and develops principally at the level of endotracheal tube or tracheostomy tube cuff. The radial pressure exerted from the cuff cau-

ses circumferential pressure necrosis, which results in cicatricial scarring stenosis (1,2). Over inflation of the cuff can result in local airway damage and subsequent scar formation. Stenosis in subglottic region may occur as a result of prolonged intubation with endotracheal tubes cricothyroidotomy or after

high placement of a tracheostomy where tube erodes through the cricoid cartilage (3).

The post intubation tracheal stenosis is a serious clinical condition and can be life threatening. Although resection and primary end to end anastomosis has been the initial treatment of choice for short stenotic segment cases but it is considered to be rather difficult treatment for long stenotic segment.

Sliding tracheoplasty although an alternative technique but involves extensive dissection and reconstruction. Pericardial patch tracheoplasty, originally described by Idriss has relatively good results. We present our experience of tracheoplasty with PTFE graft and pericardial flap with or without use of costal cartilage.

MATERIAL AND METHOD

From December 2011 to December 2012, 5 cases with severe tracheal stenosis were operated using technique of pericardial patch/flap augmentation of trachea combined to external tracheal reinforcement with strips of autologous costal cartilage or using PTFE graft.

A retrospective analysis of patient records, surgical reports, tracheobronchoscopic reports and computed tomography scan was performed to analyse the length and severity of obstruction. The preoperative diagnostic protocol included virtual computed tomography scan and bronchoscopy.

Surgical technique; Surgery was done through a median sternotomy incision extending upward just above the level of tracheostomy stoma. Anterior tracheal surface was dissected preserving the lateral vascular pedicles. The trachea was anteriorly opened along the entire length of the stenotic segment and incision was extended an extra 0.5 cm proximal and distal to the narrowed segment to ensure the complete relief of the obstruction. The tracheostomy tube pulled out and endotracheal tube introduced and positioned. In 4 out of 5 cases a patch/flap of autologous pericardium was harvested and sutured to the edges of tracheotomy using continuous 4-0 prolene sutures. In one patient out of 5 patients all the steps are similar except sternotomy and use of PTFE graft instead of pericardium (Figure 1,2).

RESULTS

All 5 patients aged between 20-30 years and were admitted with similar complaints of severe breathlessness. They had a history of different medical illnesses 3-5 month back for which they were treated in intensive care units and were on ventilatory support for 5-7 days. After that they were discharged from hospital. But soon they presented in Otorhinolaryngology department with complaints of severe breathlessness for which emergency tracheostomy was done. But despite the emergency tracheostomy symptoms could not be relieved and they are

referred to our department of Cardiothoracic and vascular surgery for further management.

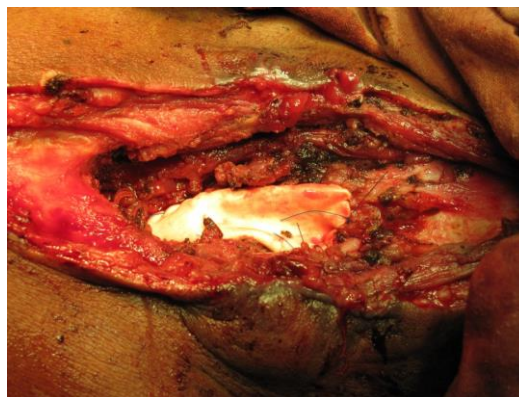


Figure 1: Intraoperative picture of prosthetic graft reconstruction of narrowed trachea.

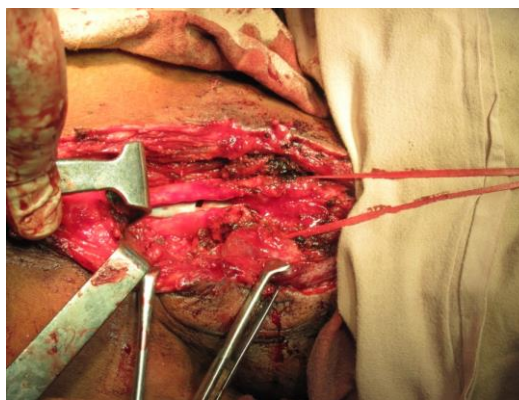


Figure 2: Intraoperative photograph of longitudinally open trachea.

On physical examination there was a tracheostomy tube in situ in all the cases and chest X ray and X ray neck showed narrowing of tracheal outline. Computed tomography scan of neck showed tracheostomy tube in situ in all cases (with surgical emphysema in neck extending to the chest wall in two cases). Computed tomography virtual bronchoscopy revealed tracheal stenosis below the tracheostomy (Figure 3-5).

DISCUSSION

The blood supply of extrathoracic trachea is from 3 nutritive branches of inferior thyroid artery therefore, tracheal ischemia leads to inflammation, granulation and eventually tracheal transmural stenosis (4). One of the most common reasons of this complication is using high-pressure cuffed endotracheal tube or tracheostomy tube, which leads to increment of pressure in the area, as well as ischemia and tracheal stenosis in prolonged usage. The high incidence of tracheal stenosis in the site near the tip of the intubations tube and the site of tracheostomy, other than the endotracheal tube cuff area, results in long and multisegmental tracheal stenosis in patients who underwent prolonged mechanical ventilation (4,5).

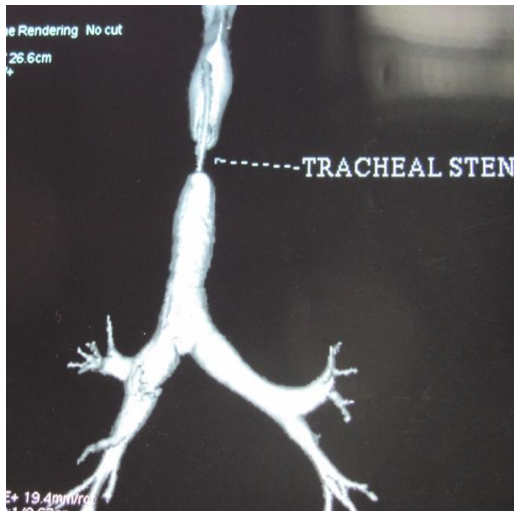


Figure 3: Showing computed tomography scan (Virtual bronchoscopy) suggestive of tracheal stenosis with stent.

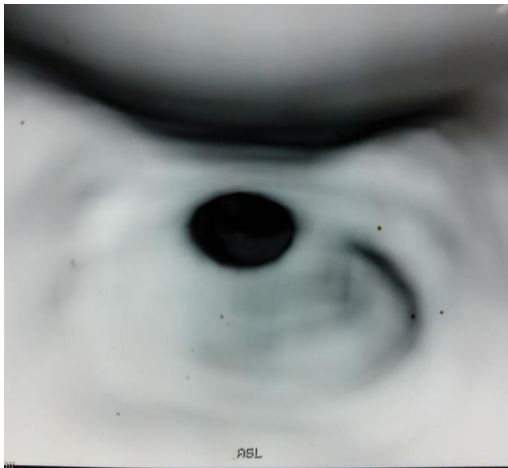


Figure 4: Showing computed tomography virtual bronchoscopy suggestive of tracheal stenosis.

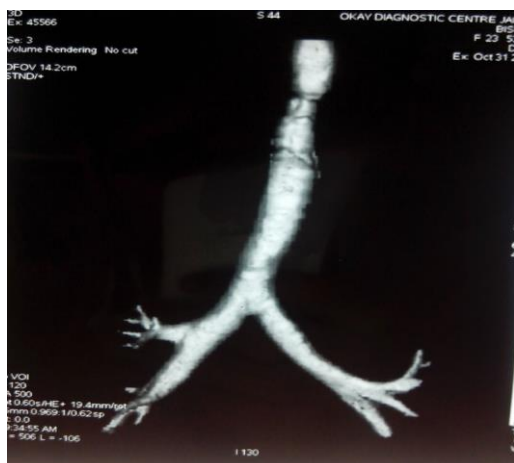

Figure 5: Computed tomography scan suggestive of tracheal stenosis.

In 4 patients with pericardial patch, strips of costal cartilage were freshened and its ends were

sutured to the edges of the trachea and pericardial patch to prevent it from infolding.

All the patients with pericardial patch/flap had an uneventful recovery. They remained intubated for 24-36 hours and then successfully extubated. They stayed in intensive care unit for 3 days and were discharged 10 days after operation.

Patient with PTFE graft was extubated on second postoperative day but soon the patient developed acute respiratory distress. Urgent re-exploration with revision of tracheal reconstruction with pericardial flap was performed but unfortunately patient did not survive.

All the patients with primary pericardial graft were discharged uneventfully and were followed regularly for a period of 6 months during which they remain asymptomatic and follow up computed tomography virtual bronchoscopy showed a wide (65-75%) open trachea with no granulation tissue formation.

Stridor is one of the prevalent signs in patients with tracheal stenosis, especially in those with the history of intubations in their past medical history. Some studies mentioned that even 24 hours of intubation is enough for this complication to occur. It should be noted that in some cases patients may be intubated long time ago and they would not remember the occasion. On the other hand, some studies showed that patients can become symptomatic even one year after intubation (6,7). With increasing number of patients are assisted with mechanical ventilation the prevalence of patients with post intubation airway stenosis has raised.

Many different techniques have been reported to reconstruct a narrowed trachea. If the length of the narrowed segment is relatively short the obstruction can be excised and tracheal repair can be done by end to end anastomosis. Longer segments can be repaired by sliding type of repair or by a pericardial patch enlargement technique (13-16). Tracheoplasty for extensive congenital stenosis using a costal cartilage insert was reported initially by Kimura and associates (17) in 1982. Idriss and colleagues (13) in 1984 described the use of pericardial patch tracheoplasty for these lesions. Granulation tissue formation has been reported not only following pericardial patch augmentation and cartilage strip repair but also after sliding and tracheal autograft reconstruction. Furthermore the shrinkage of the reconstructed trachea is not seen among the studied patients in 6 month follow up. Fanous et al. recently studied long term result of anterior pericardial tracheoplasty. There were 3 hospital deaths and 2 late deaths (at 2 and 13 years respectively) out of total 26 patients. No deaths were related to airway obstruction. Two survivors required tracheostomy postoperatively, one after formation of granulation tissue and other after failure of weaning from mechanical ventilation. All survivors remain asymptomatic with minimal to no evidence of airway obstruction. Me-

dian follow up was 11 years. The resection of long and multi segmental tracheal stenosis is one of the therapeutic difficulties which mostly affects the primary reconstruction of these patients. Grillo et al. (1995) studied 503 patients with tracheal stenosis who underwent 521 surgeries (tracheal or laryngotracheal surgeries). The result of treatment in 93.7% of patients was divided into 2 groups of good and excellent, so they mentioned that the preferable treatment is surgical resection and reconstruction of affected segment (4). In 2007, Babarro and colleagues performed a study on the long tracheal resections. They pointed out that surgical treatment is the method of choice in these cases. They also claimed that the T tube was inserted in patients with long resection at the end of the surgery. Besides, they mentioned that the suprahyoid muscle releasing maneuver and bilateral hyoid bone cutting are useful to prevent the traction in resection of proximal stenosis (9). A study by Marulli et al. (2006) reported that one time resection and primary reconstruction can be done for long stenosis with laryngeal involvement in benign stenosis, having a good long time result (approximately 93.3% for the 2 groups of good and excellent) (8). In addition, a study by Wynn R and colleagues (2004) revealed that the results of surgery and primary reconstruction in the treatment of tracheal stenosis have high success rate (10). In a study on the resection techniques of proximal long segment tracheal stenosis (more than 40% of tracheal length), Soon et al. emphasized on the releasing maneuvers especially suprahyoid muscle releasing maneuver and bilateral hyoid bone cutting. They also mentioned that hyoid bone cutting in limited resections was not necessary (5). Tracheal surgery has early and late complications. Some of the early complications are as follows: dehiscence of anastomosis resulting from excessive traction in suturing site, wound infection, respiratory tract edema. The most prevalent late complication is tracheal stenosis recurrence due to granulation tissue formation. As a matter of fact, dehiscence of anastomosis is the most dreaded, and late granulation tissue formation and wound infection are the most prevalent complications (4). The important point was that the dehiscence of anastomosis site resulting from tension in suture line occurred because of performing the tracheal releasing techniques.

Based on the fact that one of the complications in tracheal surgery is post operative granulation tissue formation which is a result of the proportional traction in the anastomosis site, choosing the appropriate suture string is important. Therefore, the sutural knot should be formed extratracheally to prevent the granulation tissue formation. In a study by Behrend et al., 3 types of absorbable suture strings (poly propylene, polydio, polyglactin) were used in tracheal surgery. They revealed that the results were similar in all 3 groups, but also mentioned that the sutural string should be with high ten-

sion ability and shouldn't be absorbed in less than 6 months. They also mentioned that technical matters especially tension are more effective than choosing the suture string in post operative results (11).

Nowadays endoscopic treatment of post-intubation benign stenosis has its own adherents. Gulluccio et al. (2009) reported that repeated dilatation, stenting or laser therapy have a role in treatment of simple and short segment post intubation tracheal stenosis, but surgery is the method of choice in long and multi segmental tracheal stenosis (12). Moreover, in a study by Nouraei SA et al. (2007) endoscopic treatments were assessed as effective procedures in post-tracheostomy limited stenosis. They claimed that surgery is the method of choice in long and multi segment tracheal stenosis (13). Cavaliere S et al. (2007) also pointed out that endoscopic treatments can be used in some specific patients as a supplementary procedure besides surgery, or as a particular method in post operative stenosis (11). In this study endoscopic treatments (repeated dilatation) were performed in post operative stenosis recurrence as a supplementary procedure, but not as the first line treatment. Because of long segment stenosis, surgery was the first choice of treatment in these patients. One of the other therapeutic methods in post operative recurrent stenosis is applying polyflex stents.

A study by Bagheri et al. (2004) revealed that the usage of polyflex stent is inappropriate due to the complications that occurred after a few months. Therefore, the stent should be removed, which can lead to granulation tissue formation and dramatic stenosis. Eventually they recommended T tube insertion in an inoperable complex stenosis (12).

Our treatment strategy for treatment of long segment of tracheal stenosis with pericardial patch/flap was associated with good outcomes. The overall success rate was 80% with no early and late complications.

In conclusion, long term endotracheal intubation and tracheostomy results in destruction of long tracheal segment causing end to end and other repairs impossible. Therefore our technique for long segment tracheal stenosis using pericardium remains a good alternative in an emergency as a life saving procedure.

REFERENCES

1. Wynn R, Har-El G, Lim JW. Tracheal resection with end- to-end anastomosis for benign tracheal stenosis. *Ann Otol Rhinol Laryngol* 2004;113:613-7.
2. Behrend M, Klempnauer J. Influence of suture material and technique on end- to-end reconstruction in tracheal surgery: an experimental study in sheep. *Eur Surg Reg*. 2001;33:210-6.
3. Galluccio G, Lucantoni G, Battistoni P, Paone G, Batzella S, Lucifora V. Interventional endos-

- copy in the management of benign tracheal stenoses: definitive treatment at long- term follow-up. *Eur J Cardiothorac Surg.* 2009;35:429-33.
4. Grillo HC, Donahue DM, Mathisen DJ, Wain JC. Postintubation tracheal stenosis. Treatment and result. *J Thorac Cardiovasc Surg* 1995;109:486-92.
 5. Soon JL, Agasthian T. Total tracheal resection for long- segment benign tracheal stenosis. *Ann Thorac Surg.* 2008;85:654-656.
 6. Cuisnier O, Righini CH, Pison CH, Ferretti G, Revt E. Surgical and/or endoscopic treatment of acquired tracheal stenosis in adult patients. *Ann Otolaryngol Chir Cervicofac* 2004;121:3-13.
 7. Tsuchida M, Hashimoto T, Shiohara H, Hosaka Y, Koike T, Hayashi J. Tracheal resection and reconstruction for tracheal stenosis. *Kyobu Geka* 2008;61:914-919.
 8. Marulli G, Rizzardi G, Bortolotti L, Loy M, Breda C, Hamad AM. Single- staged laryngotracheal resection and reconstruction for benign strictures in adults. *Interact Cardiovasc Thorac Surg* 2008;7:227-30.
 9. Babarro Fernandez R, Martinez Moran A, Martinez Vidal J, Vazquez Barro JC, Sarandeses GA. Resection with end-to-end anastomosis for postintubation tracheal stenosis. *Acta Otorrinolaringol Esp* 2007;58:16-9.
 10. Nouraei SA, Kapoor KV, Nouraei SM, Ghufour K, Howard DJ, Sandhu GS. Results of endoscopic tracheoplasty for treating tracheostomy related airway stenosis. *Clin Otolaryngol.* 2007;32:471-571-2.
 11. Cavaliere S, Bezzi M, Toninelli C, Foccoli P. Management of post-intubation tracheal stenoses using the endoscopic approach. *Monaldi Arch Chest Dis.* 2007;67:73-80.
 12. Bagheri R, Fattahi SH, Banazadeh M. The role of tracheal stenting in the alternative treatment of tracheal stenosis. *Iranian J Otorhinolaryngol.* 2005;17:147-54.
 13. Idriss FS, Deleon SY, Ilabawi MN, Gerson CR, Tucker GF, Holinger L. Tracheoplasty with pericardial patchfor extensive tracheal stenosis in infants and children. *J Thorac Cardiovasc Surg.* 1984;88:527-36.
 14. Bando K, Turrentine MW, Sun K, Sharp TG, Matt B, Heifetz SA, et al. Anterior pericardial tracheoplastyfor congenital tracheal stenosis: intermediate to long term outcomes. *Ann Thorac Surg.* 1996;62:981-9.
 15. Tsang V, Murday A, Gillbe C, Goldstraw P. Slide tracheoplasty for congenital funnel shaped tracheal stenosis. *Ann Thorac Surg.* 1989;48:632-5.
 16. Grillo HC. Slide tracheoplasty for long segment congenital tracheal stenosis. *Ann Thorac Surg* 1994;58:6113-9.
 17. Kimura K, Mukohara N, Tsugawa C et al. Tracheoplasty for congenital stenosis of entire trachea. *J Pediatr Surg.* 1982;17:869-71.