

## **TRANSVERSE COLO-COLIC INTUSSUSCEPTION IN ADULT SECONDARY TO GIT LIPOMA: A RARE CASE.**

### **Gastrointestinal sistemde lipoma bağı olarak gelişen nadir bir kolokolik intussusepsiyon olgusu.**

**Navin Kumar, Babar Rehmani, Tarun Chaudhary**

Department of General Surgery, Himalayan Institute of Medical Sciences, Dehradun, India

**Corresponding address:** Dr. Navin Kumar, surgeon\_navin@yahoo.co.in

**J Surg Arts (Cer San D), 2016;9(1):40-42.**

#### **ABSTRACT**

Adult colo-colic intussusception is rare and often originates from neoplasm as lead point. Gastrointestinal tract (GIT) lipoma is rare benign tumor. GIT lipoma causing colonic intussusception is very rare. We are reporting a case of transverse colo-colic intussusception in adult due to GIT lipoma as lead point, which is very rare. We have discussed the diagnosis and treatment of adult intussusception.

**Key words:** Intussusception, lipoma, and colon.

#### **ÖZET**

Yetişkinlerde kolonda intussusepsiyon gelişmesi nadir görülen bir durum olup, genellikle tümörlere bağlı olarak gelişir. Gastrointestinal sistemde hem lipom görülmesi hemde lipoma bağı intussusepsiyon görülmesi oldukça nadir bir durumdur. Burada, lipoma bağı olarak kolo-kolik intussusepsiyon gelişmiş bir olgu tanı ve tedavi modaliteleriyle birlikte tartışılmıştır.

**Anahtar kelimeler:** İntussusepsiyon, lipom ve kolon.

#### **INTRODUCTION**

Intussusception is defined as a condition in which there is telescoping of proximal segment of bowel into the distal bowel lumen (1). Intussusception was first reported by Barbet of Amsterdam in 1674 (2). This condition is rare in adults with occurrence of two to three cases in population of 1.000.000 per annum and accounts for less than 0.1% of all adult hospital admissions (3-5). Adult intussusception represents 5% of all cases of intussusception and accounts for only 1%-5% of intestinal obstructions in adults (6). Intussusception is idiopathic in children whereas a definable cause (lead point) is present in 70-90% of adult population, which can be malignant in up to one half of cases (7-9). Two third of adult colo-colic intussusceptions are secondary to a primary colonic cancer, remaining third are secondary to Peutz-Jegher polyps, adenoma, endometriosis, previous anastomosis and lipoma (1). Gastrointestinal

tract (GIT) lipoma is rare benign tumor. The incidence of colonic lipoma is 0.2% to 4.4% (10, 11). Colo-colic intussusception in adult is rare and often originates from neoplasm. Differentiation between benign and malignant cause of intussusception in adult is difficult without histopathological examination. Manual reduction should not be done in adult colo-colic intussusception as it may cause dispersal of the tumor (12).

#### **Case**

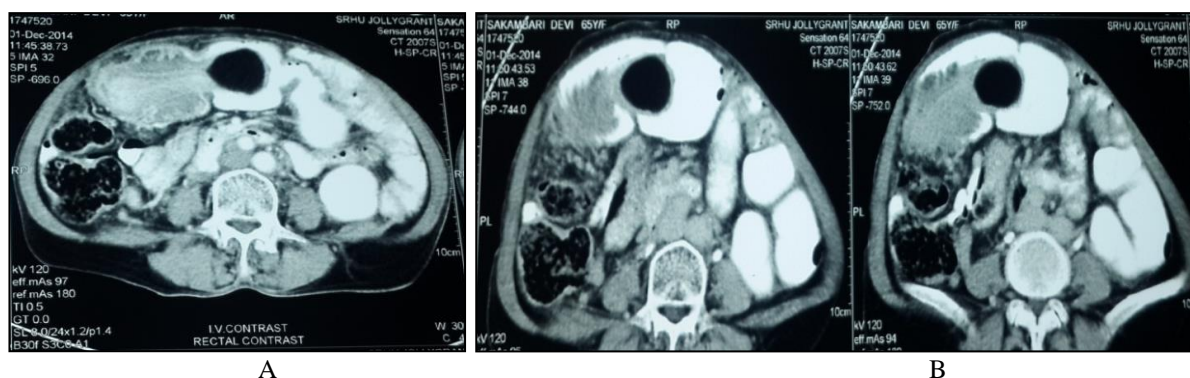
A 65 yr old female presented with complaints of lower abdominal pain and progressive abdominal distention for 1½ months. There were no history of weight loss or any surgery in past. On presentation she had PR of 98/min and BP 90/60 mmHg. Abdomen was distended and visible peristalsis present. A lump was palpable in right lumbar region and extending up to right hypochondrium.

Bowel sound was exaggerated. CECT of abdomen was suggestive of colo-colic intussusception in transverse colon with the fat density lesion as a lead point with minimal ascites. Rest of the investigations were normal. Diagnosis of large bowel obstruction with intussusception was made (Figure1).

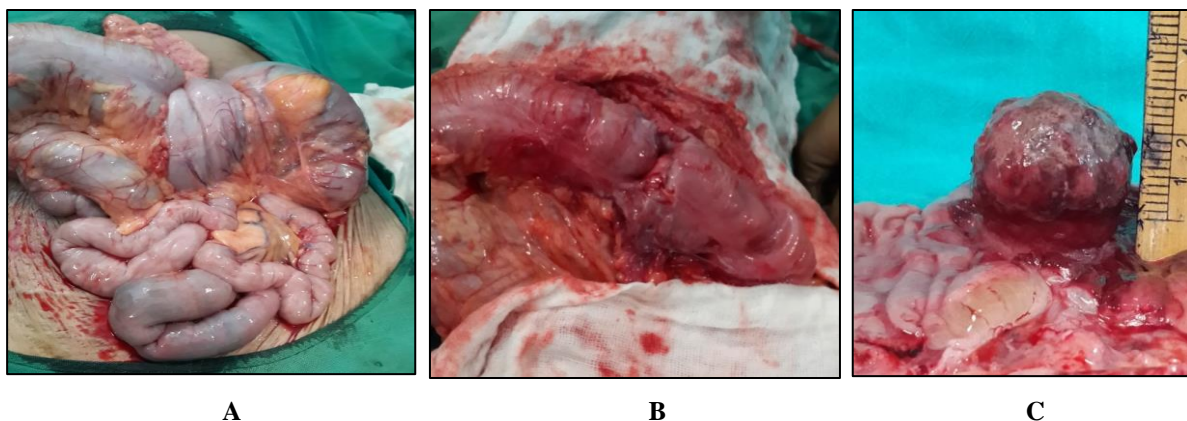
Exploratory laparotomy was done. On exploration intussusception seen in transverse colon with lead point present with oedematous bowel and enlarged epicolic and paracolic lymph nodes. Manual reduction of intussusception was successfully done and an intraluminal lead point found (Figure 2A and B).

In view of transverse colo-colic intussusception with lead point, transverse colectomy was done. On cut section of specimen a polypoidal growth of around 4x3x3 cm was found in the lumen of colon (Figure 2C). These specimens along with excised lymph nodes were sent for histopathological examination. Histopathology report was suggestive of mucosal polypoidal lipoma with areas of atrophy and congestion. Middle colic lymph node- was reactive.

After surgery, we searched the literature and found that manual reduction should not be attempted as there is increase chance of malignant origin in transverse colon intussusception. Manual reduction could cause dispersal of tumor.



**Figure 1:** CECT abdomen showing colo-colic Intussusception (A) with lead point with dilated proximal large bowel (B).



**Figure 2:** Colo-colic intussusception (A), and lead point after manual reduction (B). Excised specimen of transverse colectomy showing lipoma as lead point (C).

**DISCUSSION**

Intussusception in children is one of the main causes of intestinal obstruction, but in adults it accounts for only 1% of intestinal obstruction (13). In contrast to children where intussusceptions are idiopathic in 90% of cases, a definable cause is present in 70-90% of cases in adults (14).The mechanism is still unknown.

Secondary intussusceptions is because of lesion in the lumen or in the walls of bowel, that acts as lead point, alters normal peristaltic activity and cause invagination of proximal part of bowel

into the distal segment. This results in forward passage of contents, compromising the mesenteric blood flow in the intussuscepted part of bowel leading to obstruction and inflammatory changes and ischemia of bowel wall (1, 12).

Intussusceptions are classified on the basis of location as (i) entero-enteric , involving small bowel only, (ii) colo-colic, involving only large bowel, (iii) ileo-colic, prolapsed of terminal ileum within the ascending colon, (iv) ileo-caecal, here ileo-caecal valve acts as a lead point. It can also be classified according to etiology (benign, malignant

or idiopathic) (8,15). Two third of adult colo-colic intussusceptions are secondary to a primary colonic cancer, remaining third are secondary to Peutz-Jegher polyp, adenoma, endometriosis, previous anastomosis and lipoma (1). GIT lipoma is rare benign tumor. They were first described in 1757 by Bauer, more common in woman with a peak incidence between 50 to 60 years of age (10).

Adult colonic intussusception is rare and often originates from neoplasm. Transverse colonic intussusception is common in adult (65%) and usually has a malignant origin (1, 6, 16). Manual reduction should not be done as it may cause dispersal of the tumor (12).

Adult intussusceptions have no specific presentation. Classical pediatric presentation of cramping abdominal pain, bloody diarrhoea, and tender abdominal mass is absent. Abdominal pain, nausea, altered bowel habits and bleeding per rectum may be reported in adults (12).

Abdominal CT is currently considered as most sensitive radiologic method, with accuracy of 58-100% (6). Characteristic feature is 'target' or 'sausage' shaped soft tissue mass with a layering effect (1,17). Colonoscopy allows visualization of lipoma; characteristic endoscopic features include 'cushion sign', 'naked fat sign' (18). Large lipoma >2 cm during endoscopic removal are at risk of perforation, therefore should be surgically resected (19).

Adult intussusception warrants laparotomy rather than attempts at hydrostatic reduction in view of the high incidence of underlying abnormality (6). Begos et al. suggest resection without attempting reduction when the bowel is inflamed, ischaemic, or friable and in obvious colo-colic intussusception (given the high likelihood of malignancy) (1). However, Azar et al. suggested that surgical resection without reduction is the preferred treatment in adults, as almost 50% of both colonic and enteric intussusceptions are associated with malignancy (6).

## REFERENCES

- Begos DG, Sandor A, Modlin IM. The diagnosis and management of adult intussusception. *Am J Surg.* 1997;173:88-94.
- Barbette P. *Oeuvres Chirurgiques at Anatomiques.* Geneva: Francois Miede, 1674
- Carter CR, Morton AL. Adult intussusception in Glasgow, UK. *Br J Surg.* 1989;76:727.
- Donhauser DL, Kelly EC. Intussusception in the adult. *Am J Surg.* 1950;79:673-7.
- Brayton D, Norris WJ. Intussusception in adults. *Am J Surg.* 1954;88:32-43.
- Azar T, Berger DL. Adult intussusception. *Ann Surg.* 1997;226:134-8.
- de Moulin D, Barbette P. A seventeenth-century Amsterdam author of best-selling textbooks. *Bull Hist Med.* 1985; 59: 506-4.
- Nagorney DM, Sarr MG, McIlrath DC. Surgical management of intussusception in the adult. *Ann Surg.* 1981;193:230-6.
- Haas EM, Etter EL, Ellis S, Taylor TV. Adult intussusception. *Am J Surg.* 2003;186:75-6.
- Rogy MA, Mirza D, Berlakovich G, Winkelbauer F, Rauhs R. Submucous large – bowel lipomas – presentation and management. An 18 year study. *Eur J Surg.* 1991;157:51-5.
- Vecchio R, Ferrara M, Mosca F, Ignoto A, Latteri F. Lipomas of the large bowel. *Eur J Surg.* 1996;162:915-9.
- Marinis A, Yiallourou A, Samanides L, et al. Intussusception of the bowel in adults: a review. *World J Gastroenterol.* 2009;15 :407-11.
- Briggs DF, Carpathios J, Zollinger RW. Intussusception in adults. *Am J Surg* 1961;101:109-13.
- Agha FP. Intussusception in adults. *Am J Roentgenol* 1986;146:527-31.
- Stubenord WT, Thorblamarson B. Intussusception in adults. *Ann Surg.* 1970;172:306-10.
- Lorenzi M, Iroatulam AJN, Vernillo R, et al. Adult colonic intussusception caused by a malignant tumor of the transverse colon. *Am Surg.* 1999;65:11-4.
- Kim YH, Blake MA, Harisinghani MG, et al. Adult intestinal intussusception: CT appearances and identification of a causative lead point. *Radiographics* 2006;26:733-44.
- Messer J, Wayne JD. The diagnosis of colonic lipomas-naked fat sign. *Gastrointest Endosc.* 1982;28:186-8.
- Pfeil SA, Weaver MG, Abdul-Karim FW, Yang P. Colonic lipomas: outcome of endoscopic removal. *Gastrointest Endosc.* 1990;36:435-8.